

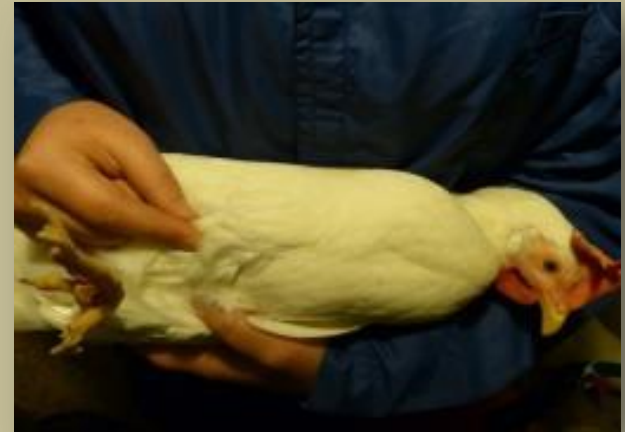# IMPROVING AND VALIDATING KEEL BONE PALPATION

Ariane Stratmann  
ZTHZ, Division of Animal Welfare  
University of Bern  
Switzerland



# KBD ASSESSMENT USING PALPATION

- The most commonly used method to assess KBD on farm as well as in experimental studies
- Scanning the keel with fingers along the *carina sterni*  
→ any abnormalities from a smooth, straight bone e.g. sharp bends and edges, indentations and s-shaped deformations
- Status of the keel bone → categories



# SCORING SCHEMES

## *Scholz et al. 2008*

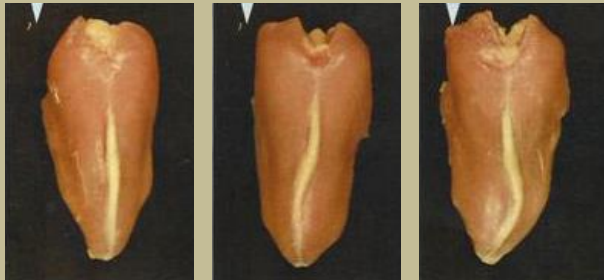Score 4: no deformity

Score 3: slight deformity

Score 2: moderate deformity

Score 1: severe deformity

→ Including fractures & deviations



## *Wilkins et al. 2004*

Fracture 0,1,2

Detailed scores for dissected bones





Severity scale of keel fractures from 0 (normal) to 4 (severe), left to right

→ Other studies using modified scoring schemes including both

(Käppeli et al., 2011; Heerkens et al., 2013; Stratmann et al., 2015a,b; Habig & Distl 2013)

# ADVANTAGES AND LIMITATIONS

	
<ul style="list-style-type: none"><li>• Fast, cheap and easy to perform</li><li>• Validated scoring schemes</li><li>• Independent of setting</li></ul>	<ul style="list-style-type: none"><li>• No detailed information on KBD</li><li>• Risk to miss fractures (size, location)</li><li>• Risk to misinterpret (false positive, negative)</li><li>• Often poor accuracy and repeatability</li></ul>

## Requirements

- Appropriate training of palpation technique
- Regular recalibration
- Number of animals varying in damage type and severity (Petrik et al., 2013)

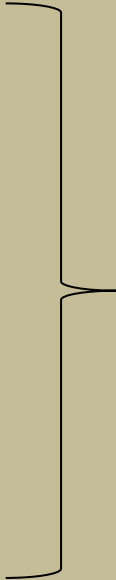
# SUGGESTIONS FOR IMPROVEMENT

Casey-Trott et al., 2015

## KBD Workshop Bern 2014

### Recommendations:

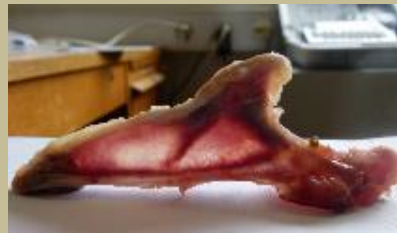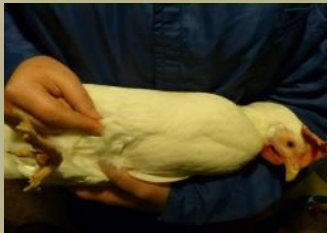- **SKAP** Simplified Keel Assessment Protocol
  - > Fractures yes/no
  - > Deviations yes/no
- Report of accuracy and reliability
- Standardised training protocol

















Improve reliability of  
method and  
comparability of results

# PALPATION TRAINING ZTHZ

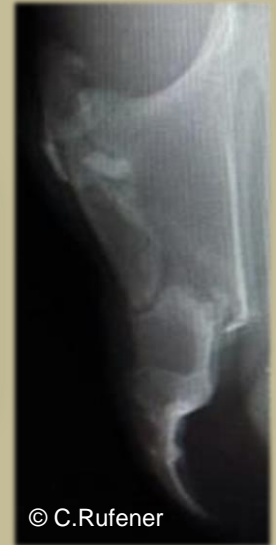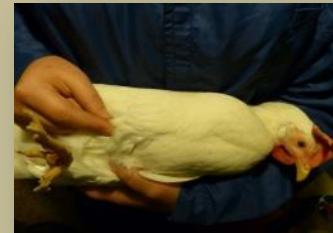- Palpation of same birds
- Write and draw damage type and location → visualization
- Dissection of keel bones and comparison with palpation outcome
- Group discussion on causes and type of injury



	Palpation	Dissection
Hen ID:		
Hen ID:		
Hen ID:		
Hen ID:		
Hen ID:		
Hen ID:		
Hen ID:		

# USING X-RAY AS VALIDATION OF PALPATION

- X-ray as an alternative to palpation → PhD project Christina Rufener
- Use X-ray to validate palpation → individual training and recalibration of technique
  - How does what I feel look like?
  - How does a fracture feel like?
  - What is it exactly I feel?
  - How much do I miss?
- Result: more false positives → finetuning of technique
- Training every few months to refresh and adjust palpation technique, also with whole group



# IMPROVING OBSERVER RELIABILITY OF PALPATION BY 3D PRINTABLE MODELS



- Template: Keel bones of different categories
- Files can be distributed easily and plastic models printed by 3D printer everywhere
- Plastic models in the pocket during farm visits can be «palpated» along with keel bones of live birds
- A tagged *tactile* analog scale for scoring can be used

Aim: Keel bone damage including deviations and fractures can be scored similarly by different research groups.  
Suitable for training and retraining sessions.

Prof. Michael Stoffel (Department of Anatomy, Vetsuisse Bern) has experience with 3D printable anatomical models and offered support.



# CONCLUSION

- Palpation method No. 1 to assess KBD → effort to standardize and improve
  - SKAP and training protocols
  - Validation using X-ray
- Training school

«Standardizing palpation of keel bones»

Fall 2017: Training school at ZTHZ in Zollikofen CH