Fractures, bone healing and pain in birds

Jean-Michel Hatt

Prof.Dr.med.vet., Dipl ACZM, Dipl ECZM (avian)

Learning objectives

- Recognize main parts of the avian skeleton
- Understand the main aspects of bone physiology and specifically of bone healing, with special emphasis on the sternum
- Understand the differences between fractures in mammals and birds
- Recognize the importance of pain and analgesia in avian medicine

Avian skeletal system

- Based on sternum two main avian subclasses: ratities (flightless birds) and carinates all other
- Keel of importance for muscle insertion
- Largest carinate is the Andean condor (approx. 15 kg)
- Skeleton adapted to flight

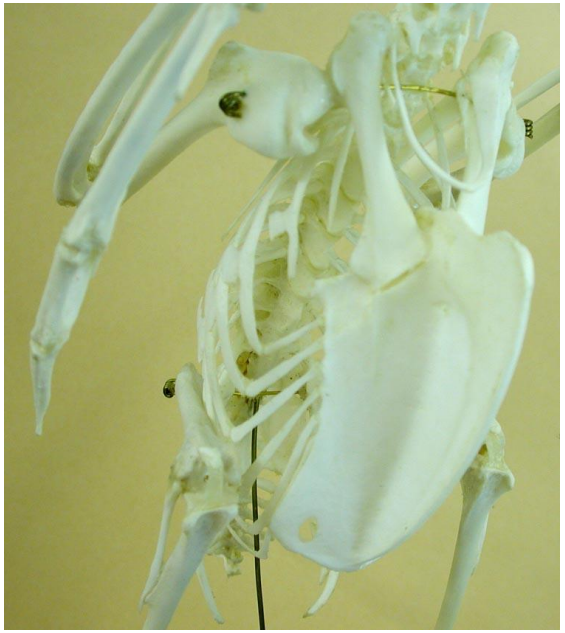

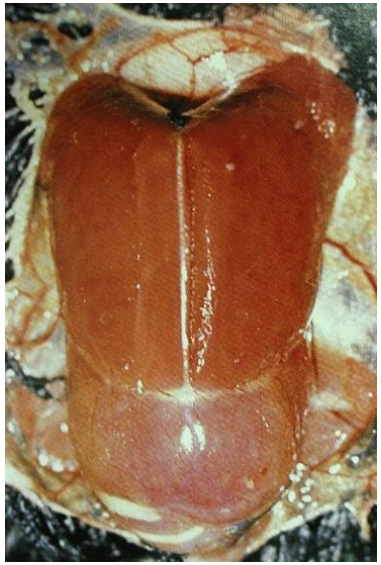

Adaptations to flight

- Modification of forelimb for flight, bill and neck for prehension
- Lightweight fused skeleton
  (approx. 4 to 9% of body weight, upto 30% in mammals)
- Bones contain higher amount of anorganic substances
  (75% vs approx. 66% in mammals) – stronger but more brittle bone
  (comminuted fractures)
- Airsacs extend into the medullary cavity of major bones: humerus, (femur), coracoid, pelvis, sternum and vertebrae
  (variations according to species).

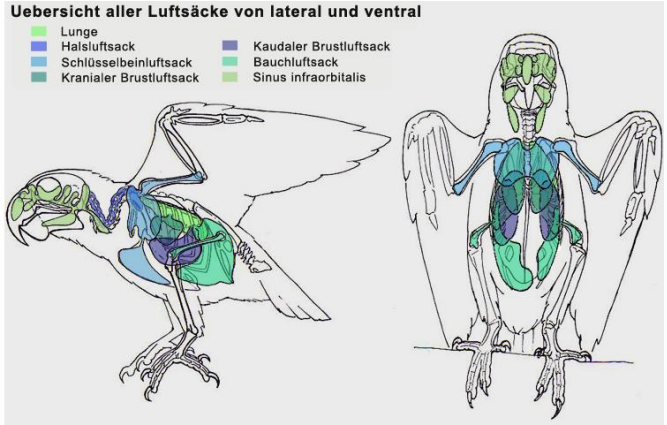

Overview

Special emphasis on sternum

- Protection and flight muscle insertion (adduction and abduction of wings)
- Keel bone (carina) length proportional to flight
- Caudal portion may be perforated (failure to ossify) especially in poor flyers (poultry)
- Connection to pectoral girdle (coracoid, scapula, calvicle)

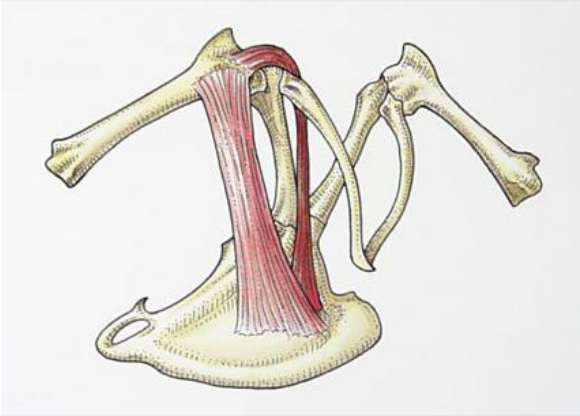

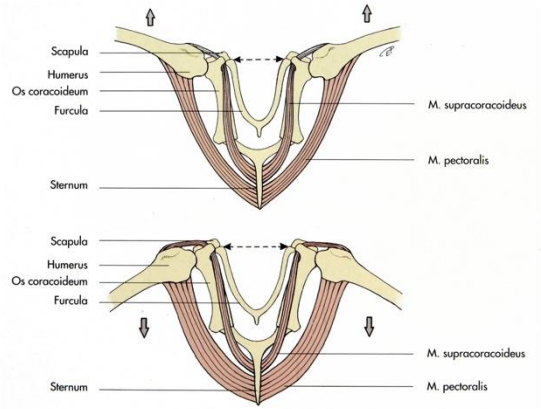

König & Liebich, 2001

Sternum in chicken (Example backyard hen)

Bone physiology

- Growth and ossification similar to mammals
- Ossification on a cartilaginous model like mammals
- Secondary centres of ossification often absent (exception e.g. tibiotarsus birds of prey)
- Cortex relatively thin (1/2 mammals), medulla is stabilised by trabecula
- Vit D, calcium and phosphorus balance for healthy development

Bone physiology

- Structural bone: cortical and cancellous
- Medullary bone
- Medulla in females is important calcium storage, resulting in an increase of weight of skeleton by approx. 20%
- One egg shell in chicken can contain up to 10% of calcium store
- Medullary bone grows from the endostal surface

Comparison

Backyard chicken

Battery laying chicken

Bone physiology

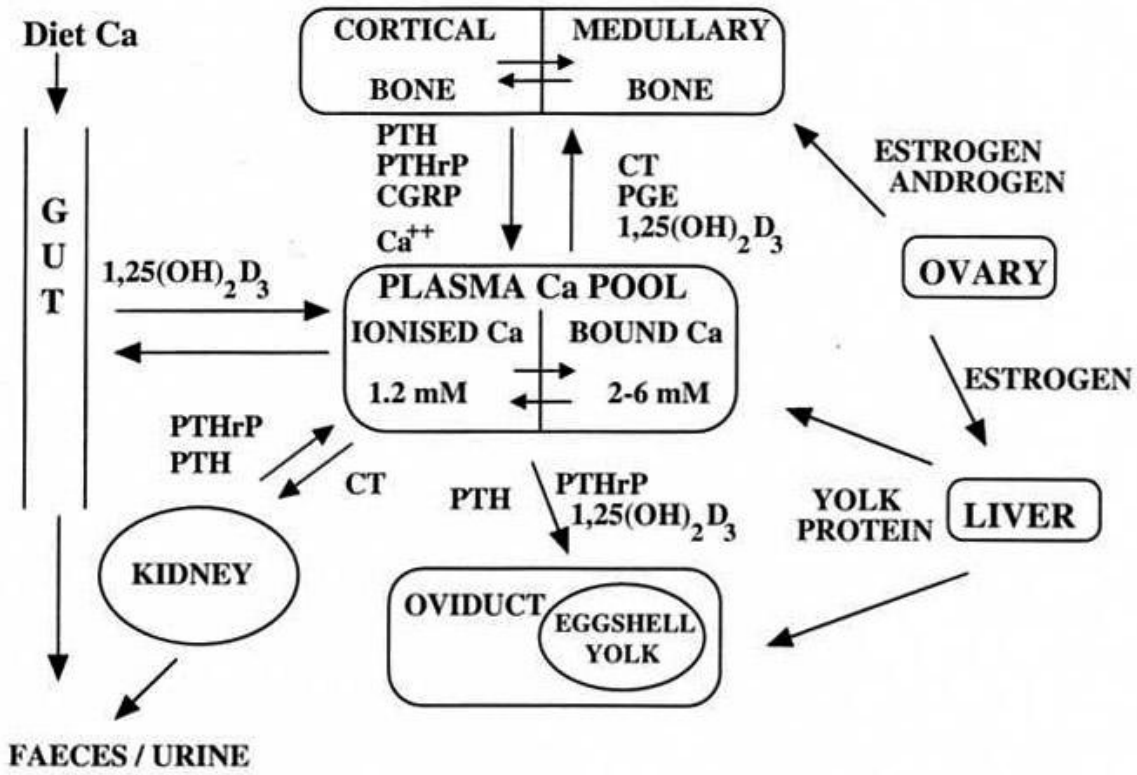

FIGURE 6 Summary of Ca metabolism in egg laying birds. Plasma Ca levels are very high in hens due to binding by yolk protein precursors. Transfer of Ca (and Pi) between dietary, plasma, structural and medullary bone pools and across the oviduct may be influenced by a variety of recognised and putative hormonal factors (see text).

Fractures in birds

- Exposed bones
  (Low breast muscle in laying hens leaves keel exposed!)
- Typically long bone fractures (pet birds: legs / wild birds: wings)
- Coracoid fractures in birds of prey
- Sternal fractures very rare 0.4% (1/237) in wild birds (Herrmann, 2009)
- Fractures may result in emphysema and comminution

Fractures in birds

Pathologic fractures

•Dietary and / or genetic:
Metabolic bone disorders (e.g. rachitis, osteoporosis) – deformity may be followed by fracture

•Infection (e.g. Mycobacteria)

•Minor tauma needed for fractures to occur
(e.g. depopulation and transport in chicken, increased activity Directive 1999/74/EC! – Fleming et al., 2004)

Universität Zürich[UZH]

Klinik für Zoo-, Heim- und Wildtiere

Deformed Sternum
Laying Hen

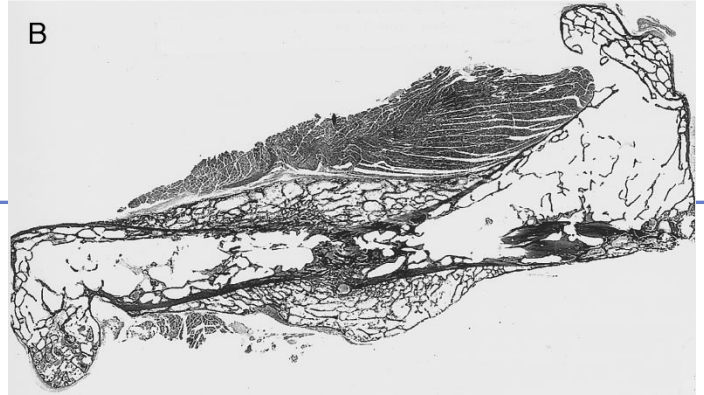

Wander et al. 2000

Fracture healing in birds

- Similar to mammals:
  inflammation – soft callus / connective tissue,
  remodeling – hard callus / cortical union

- Endostal and periostal callus – amount depends on fracture fixation

- Egg laying interferes with bone healing!
  Under medullary bone development results in cessation of remodeling of structural bone! (Whitehead & Fleming 2000)

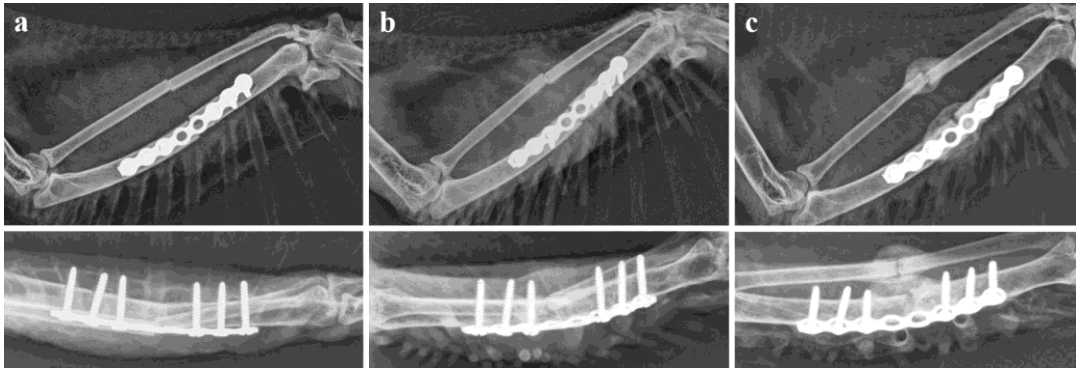

Figure 1. Two-view radiographs of a pigeon in group A (1.3-mm adaption plate) after transection of the radius and ulna (a) 3 days after ulnar surgery, (b) 14 days after surgery, and (c) 28 days after surgery.

Bennert et al. 2016

Fracture healing in birds

- Primary healing rare (needs excellent stabilisation)
- Fracture healing typically faster in avian bone than in mammals
- Duration 3 – 12 weeks (Cooney & Mueller, 1994)
- Load bearing increases fracture healing (dynamisation)
- Influencing factors: vascularisation, degree of dislocation, stabilisation, hormones, dietary factors
- Estrogen treated birds have shown reduced callus strength and an increased diameter of the callus owing to an instability of the fracture site (Engin et al., 1983)

Fracture healing in poultry with osteoporosis

- Single bone fracture keel (unlikely) vs. multiple fractures (likely)
- Spontaneous healing possible if food and water readily available
  (9/12) but with permanent problems (e.g. abnormal gait – 9/9)
  (Riddell et al., 1968)
- Supplementation with Vit D and Calcium discussed
- Oyster shell (larger pieces – to stay in ventriculus)

Splints

- Upto BM 300 g often method of choice
- Altman splint
- U-shaped SAM splint
- Healing 4 – 8 weeks

Bandage

- Figure of eight
- Carpometacarpus
- Ulna or radius
- Coracoid
- Stabilisation before surgery

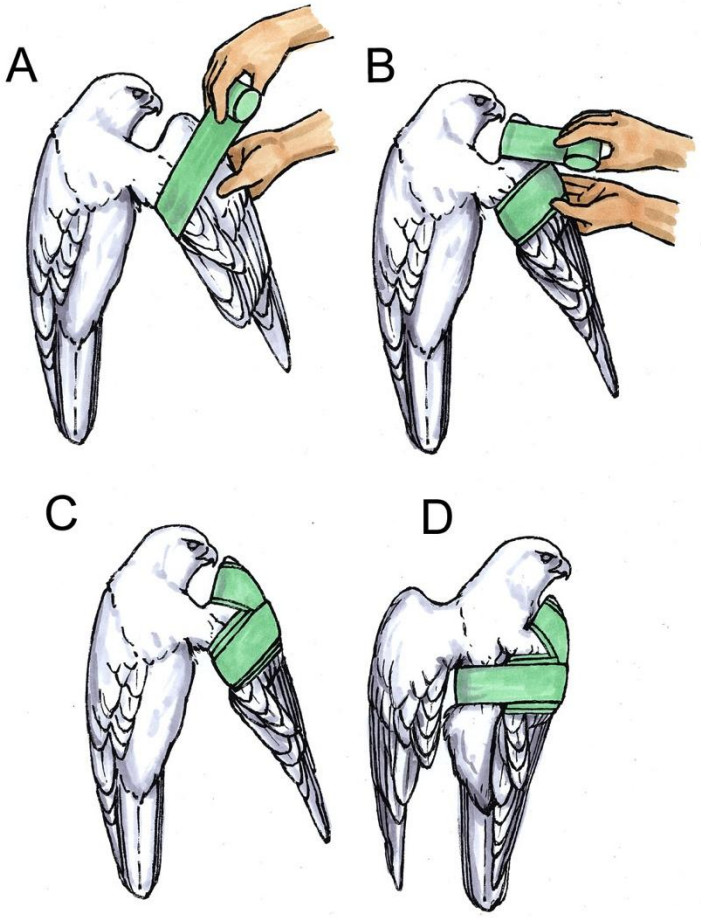

Plating

- Distal fractures
  (Small fragments)
- In closed fractures- HOWEVER Opening of fracture
- Good stability – Primary healing aim
- High demands (Material, instruments, surgical skills)
- Price

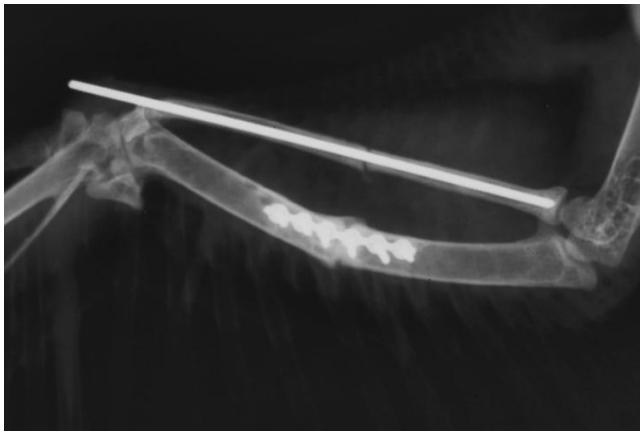

Intramedullary pins

- Little equipement necessary
- Simple and cheap method
- Involvement of joint
- Rotation stability often inadequate!
- Opening of fracture ?



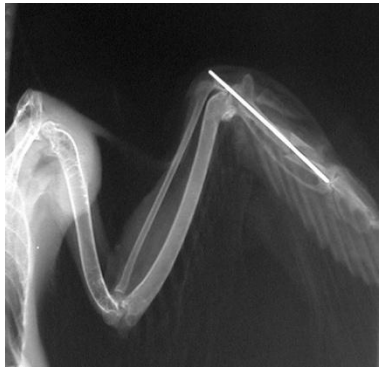

Conclusion

- May be used in small (distal) bones
- Emergency method

External fixation

- External connecting bar + Pins
- Typ 1 (Tie in-method) and Typ 2 fixator
- Opening of fracture not always necessary
- Little impairment of blood supply
- Often method of choice

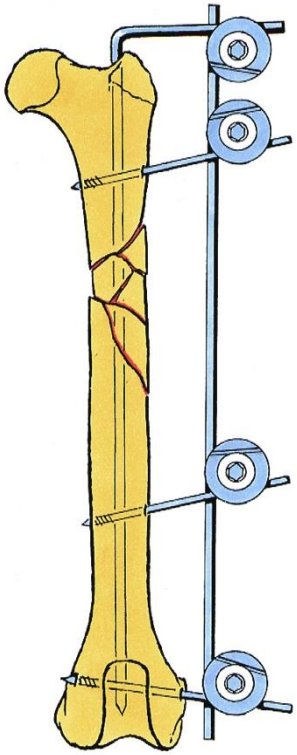

Pain and pain management in birds

- Acute vs. chronic pain
- Pain results in physiological and behavioural reactions (as in other vertebrates)
- Pain management in general similar to other animals
- Pain recognition and assessment in birds is difficult - no facial expression and no vocalisation
- In chickens removal of feathers caused a progression of behavioural changes from an alert agitated response following the initial removal of feathers to periods of crouching immobility following successive feather removal (Gentle & Hunter, 1991)
- Separation of group
- Pain score sheet (pigeon)

Pain and pain management in birds

- Birds have been described as possessing primarily kappa-receptors, and they do not respond consistently to mu-opioid analgesics. – Butorphanol more frequently used.

- Beware of species differences!

- **Analgesia**:

Butorphanol	1 – 2 mg/kg IM	(Duration approx. 2 - 4h)
Tramadol	10 – 30 mg/kg PO	(Duration approx. 8h)
Meloxicam	1 – 2 mg/kg PO, IM	(Duration 12h)

- Flunixin meglumine

- 1.1 mg/kg IV — several hours in chicken
  3.0 mg/kg IV — onset after 1 h in chicken

- Ketoprofen 12 mg/kg IM — onset after 1 h in chicken

Important points

- Avian bone presents important differences compared to mammals: pneumatisation, medullary bone formation, thin cortex
- Sternal fractures due to osteoporosis are pathologic fractures
- Healing possible but hampered in laying hens due to permanent presence of medullary bone
- Assessment of pain challenging in birds – necessity to develop pain score in chicken in relation to sternal fractures
- Increasing knowledge regarding analgesia must be included in management of fractures in birds

Thank you for your attention!

Bild: Edi Day